

# Effectiveness of Three Steps Hysteroscopic Repair of Isthmocele in Patients with Post Menstrual Spotting

Original  
Article

Mervat A. Elersy

Department of Obstetrics and Gynecology, Faculty of Medicine, Alexandria University, Egypt

## ABSTRACT

**Objectives:** Asses the effectiveness of three steps resection method of an isthmocele using hysteroscopy in patients complained of postmenstrual bleeding with confirmed presence of isthmocele.

**Study Design:** Prospective interventional cohort study.

**Patients and Methods:** 50 patients complained of postmenstrual bleeding with confirmed presence of an isthmocele. After written consent, the patients have been subjected to three steps hysteroscopic resection of an isthmocele by removing the distal edge of the niche then the proximal edge and lastly ball cauterization of the floor of the pouch of the isthmocele. Post-operative transvaginal ultrasound and follow up for 2 menstrual cycles were performed for all patients.

**Results:** The median duration of menstruation shortened from 13 days to 7days after surgery ( $p < 0.01$ ). The median duration of postmenstrual spotting improved from 6 days (range 5-7 days) to 2 day (range 0–3 days) at follow-up ( $p < 0.01$ ). Follow up transvaginal ultrasound showed significant reduction of the niche depth from  $5.2 \pm 1.1$  mm to  $2.3 \pm 1.3$  ( $p < 0.01$ ).

**Conclusion:** Hysteroscopic repair of post caesarean isthmocele in patients with post menstrual spotting is considered an effectiveness minimally invasive choice of treatment.

**Key Words:** Cesarean section, hysteroscopy, isthmocele, postmenstrual bleeding. .

**Received:** 27<sup>th</sup> May 2022, **Accepted:** 14<sup>th</sup> June 2022

**Corresponding Author:** Mervat A. Elersy, Department of Obstetrics and Gynecology, Faculty of Medicine, Alexandria University, Egypt, **Tel.:** +20 10963 11548, **E-mail:** msersy@hotmail.com

**ISSN:** 2090-7265, August 2022, Vol.12, No. 3

## INTRODUCTION

The caesarian section (CS) rate increased obviously in Egypt, especially in the private sector<sup>[1]</sup>. An isthmocele or CS scar defect, which is defined an indentation of at least 2 mm on the side of the uterine cesarean scar, which is a known complication of CS<sup>[2]</sup>.

The etiology of development of an isthmocele is unclear, many postulations had been described. It may be due to defective tissue healing and dehiscence in the myometrium secondary to reduced vascular perfusion<sup>[3]</sup>. In addition to several other factors that may also play a role in the pathogenesis of defective cooptation of uterine tissue such as the level of incision at the lower uterine segment, the stage of labor when the CS was performed<sup>[4]</sup> or uterine closure technique used during the operation<sup>[5]</sup>.

The frequently reported symptoms of women with an isthmocele are abnormal uterine bleeding in the form of post menstrual spotting, secondary infertility, pelvic pain and dysmenorrhea<sup>[6,7]</sup>. Not only but also the presence of an isthmocele could be also an etiological factor of many other complications such as uterine rupture, caesarean scar ectopic and difficult embryo transfer<sup>[8]</sup>.

Post menstrual spotting or intermenstrual spotting is due to accumulation and retention of menstrual blood in the pouch like space at CS defect in addition to the development of fragile vessels at the bed the isthmocele that easily bleed and add to the formation of blood or fluid in the uterine cavity<sup>[9]</sup>.

An isthmocele can be diagnosed by using transvaginal ultrasonography (TVS), with or without saline or gel contrast<sup>[10]</sup>, magnetic resonance imaging (MRI)<sup>[11]</sup>, and hysteroscopy<sup>[12]</sup>.

There are several techniques described for the correction of isthmoceles. Isthmoplasty can be performed by hysteroscopy, laparoscopy<sup>[13-15]</sup> or vaginal surgery<sup>[16]</sup>.

According to the most recent literature, hysteroscopy seemed to be an excellent option for management of women with an isthmoceles with a residual myometrial thickness of at least 3 mm to improve postmenstrual bleeding<sup>[14,17]</sup>.

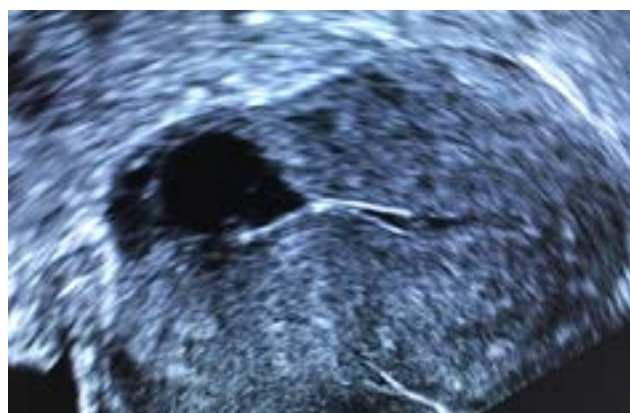
This study aimed to assess the effectiveness of three steps resection method of an isthmocele using hysteroscopy in patients complained of postmenstrual bleeding with confirmed presence of an isthmocele.

**PATIENTS AND METHODS**

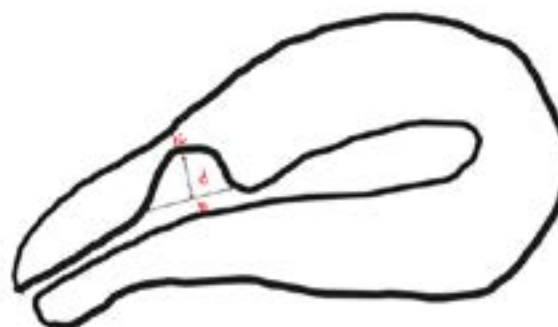
This prospective study included 50 patients who presented to Shatby Maternity University Hospital between 16 July 2021 until October 2021 and the study was approved by the Faculty of Medicine Ethical Committee: 0305227. ClinicalTrials.gov identifier (NCT number): NCT05062551. All women fulfilled the inclusion criteria gave an informed consent. The study was conducted in accordance with the ethical standards established in the Declaration of Helsinki of 1946.

The women included in the study were those with previous caesarian section (CS) and complained of post menstrual bleeding or spotting. Post menstrual spotting was diagnosed as the presence of three or more days of spotting or brownish discharge after the end of 7days menstruation for at least 3months post CS or inter-menstrual bleeding for more than 2days. Exclusion of other causes of bleeding was confirmed by history, examination, investigation and ultrasound evaluation of the pelvis. Women with IUD or on any hormonal treatment or had genital tract malignancy were not included in the study.

Characterization of the scar defect (isthmocele) was done using trans- vaginal ultrasound in the proliferative phase, isthmocele was recognized as an anechoic triangular-shaped area, with the apex towards the bladder, in the anterior uterine wall at the site of (CS) scar. Depth, base, area of the defect and the residual myometrial thickness (RMT) at the apex of the isthmocele, were measured as demonstrated in (Figures 1,2). Also thickness of adjacent myometrium was measured (AMT). Any patient whose RMT was <2.5 mm was excluded from the study. Area of the defect was calculated as an area of a triangle (area =base×depth÷2 ). Further sub classification of the defect into grades according to the area measured as grade 1, if the area <15 mm<sup>2</sup> or grade 2, if the area was between 16-25mm<sup>2</sup> and grade 3, if the area was >25 mm<sup>2</sup>.



**Fig. 1:** Transvaginal ultrasound picture of uterine isthmocele



**Fig. 2:** Diagrammatic illustration of how to characterize uterine isthmocele

b:base of the isthmocele  
d: depth of the isthmocele  
c: residual myometrial thickness

Area of the defect was calculated as (area =base×depth÷2)

All women were subjected to operative hysteroscopy, which was performed under general anesthesia, using glycine distension media, by using a 9mm, 30° angle lens, rigid resectoscope (Karl Storz GmbH and Co, Tuttlingen, Germany). Direct visualization of the uterine cavity to exclude other intrauterine pathologies was done. Then hysteroscopic niche resection was performed using a mono-polar resectoscope loop. Distal and proximal edges of the isthmocele were identified. The distal arch was resected first then the proximal arch until the bottom of the isthmocele reached the level of the cervical canal. And lastly the bottom of the isthmocele was treated using a 3-mm electro cauterization rollerball as demonstrated in (Figure 3) all procedures were performed by only one experienced surgeon.



**Fig. 3:** Diagrammatic illustration of the procedure steps

1: identification of the isthmocele.  
2: after resection of distal arch of the isthmocele.  
3: after resection of the proximal arch and cauterization of the bed of the isthmocele.

Post-operative outcomes to be measured were: change in postmenstrual spotting duration during the postoperative follow-up 2 menstrual cycles compared with preoperative baseline. The sonographic parameters changes of the niche will be also assessed postoperatively such as depth of the niche, residual myometrial thickness and the presence of intrauterine fluid.

**Statistical analysis**

One-sample Kolmogorov–Smirnov test was used for normality test. Follow-up data were compared with baseline data using paired t-tests if normally distributed

and equally varied; otherwise, paired non-parametric tests were used. A *p* value of < 0.05 was considered statistically significant.

## RESULTS

Analysis of the demographic data of patients in the study group was shown in (Table 1). The patients age ranged from 21 to 38 years old. All our patients were multi-para with previous one or more cesarean sections. Two patients had intrauterine surgeries in the form of dilatation and curettage. None of them used anticoagulants. The body mass index ranged from 19 to 37 kg/m<sup>2</sup>.

Comparison between pre and post-operative data of the study group are shown in (Table 2). Analysis of data showed significant reduction of the median duration of menstruation from 13 days (range 10–15 days) to 7 days (range 5–8 days) after surgery (*p* < 0.01). Also the median duration of postmenstrual spotting was significantly decreased from 6 days (range 5-7 days) to 2 day (range 0–3 days) at follow-up (*p* < 0.01). Follow up transvaginal ultrasound was done after two menstrual cycles post resection showed significant reduction of the niche depth from 5.2±1.1 mm to 2.3±1.3 (*p* < 0.01). All operations for niche resection were scheduled post menstrual. No complication was detected intra-operatively or post-operatively, this could be due to exclusion of patients whose RMT was less than 2.5 mm. There was non-significant difference between pre and post-operative residual myometrial thickness (RMT) at the apex of the niche, because all hysteroscopic procedures were done by experienced surgeon.

**Table 1:** Demographic data of the study group (n=50)

Age in years(mean –range)	31(21-38)
BMI kg/m2(mean –range)	30.8(19-37)
parity(mean –range)	2(1-4)
Number of previous CS(mean –range)	2 (1-4)
Time lapse of last CS(mean –range)	0.6(12-46)
Smoking (number & %)	3(6%)
Use of anticoagulants (number & %)	0
History of intrauterine surgeries (number & %)	2 (4%)

**Table 2:** Comparison between pre and post-operative data

Bleeding characteristics	Before resection(n=50) mean & range	After resection(n=50) Mean & range	<i>p</i>
Total days of menstrual spotting	13 (9-16)	7 (5-8)	<0.01
Postmenstrual spotting	6(5-7)	2(0-3)	<0.01
Ultrasound findings	Mean ±SD	Mean ±SD	
Depth of the niche in mm	5.2±1.1	2.3±1.3	<0.01
Residual myometrial thickness in mm	4.2±0.9	3.9±1.0	0.23
Intrauterine fluid	23	4	<0.01

## DISCUSSION

There is no agreement which is the best surgical approach to treat a symptomatic isthmocele but the residual myometrial thickness is still a crucial parameter to be considered when planning for management.

In this study, hysteroscopic resection of the isthmocele by the three steps method was an effective approach as it improved the post menstrual spotting significantly and reduced the total days of menstrual spotting also significantly. In addition, no complication occurred for any of our patients'. This proves that hysteroscopy is an ideal tool for management in patient with RMT > 2.5mm. Improvement in the abnormal uterine bleeding was in line with results of other previous studies<sup>[2,14,18-20]</sup>.

Zeller A *et al* concluded that hysteroscopic approach was a sufficient way to treat isthmocele even when the residual myometrium was thinner than 3mm<sup>[17]</sup>, which is not the same conclusion of Setubal A. *et al*, who stated that Laparoscopic approach with concomitant hysteroscopy is a good option if residual myometrium is <3 mm<sup>[21]</sup>.some researchers preferred laparoscopic repair of the uterine isthmocele and they proved that laparoscopic repair increased the thickness of residual myometrium significantly and this thickening persisted even after subsequent CS<sup>[13,15]</sup>.

In our study there was non-significant difference between pre and postoperative residual myometrial thickness after hysteroscopic repair of the isthmocele which does not match with the observation of Tsuji, S *et al* who observed increase in the residual myometrial thickness post hysteroscopic resection<sup>[22]</sup>. This could be due they removed the inferior edge only, while in this study we removed both the proximal and distal edges together with base cauterization.

The study had many points of strength; one of them is the identical method of the resection done by an experienced surgeon who followed predefined steps described in the study protocol. Also there was no loss of patients in the follow up visits due to concise duration which was two menstrual cycles post resection. Also none of patients received any hormonal medication or other anti-bleeding drugs which allowed for accurate correlation between the procedure and the decrease of spotting.

Limitations of the study was lack of surveys about menstruation related pain, discomfort or satisfaction with menstruation at baseline and at follow-up. In this study the objective outcome evaluation focused on the number of days of spotting as a sold outcome to be measured. Other researchers already did the lacked surveys in our and they assessed patient expectation and satisfaction, they reported that the majority of the patients were satisfied with the outcomes of hysteroscopic niche resection even

## ***hysteroscopic repair of symptomatic isthmocele***

---

with a minimal reduction of 3 days in the duration of postmenstrual spotting<sup>[23,24]</sup>.

Further studies are needed to test the effectiveness of the described method, three steps hysteroscopic resection, on the reproductive performance and the occurrence of CS scar rupture during subsequent pregnancies.

### **CONFLICT OF INTERESTS**

---

There are no conflicts of interest.

### **REFERENCES**

---

1. Jadoon B, Assar TM, Nucier A, Raziq HEA, Abd El-Azym Saad AS, Megahed Amer W. Analysis of the caesarean section rate using the 10-Group Robson classification at Benha University Hospital, Egypt. *Women Birth*. 2020;33(2):e105-e10.
2. Torre A, Verspyck E, Hamamah S, Thomassin I, Thornton J, Fauconnier A, *et al.* [Caesarean scar niche: Definition, diagnosis, risk factors, prevention, symptoms, adverse effects, and treatments]. *Gynecol Obstet Fertil Senol*. 2021.
3. Iannone P, Nencini G, Bonaccorsi G, Martinello R, Pontrelli G, Scioscia M, *et al.* Isthmocele: From Risk Factors to Management. *Rev Bras Ginecol Obstet*. 2019;41(1):44-52.
4. Sisti G, Nasioudis D, Kanninen T, Sorbi F, Fambrini M. Risk factors for development of isthmocele following cesarean section. *Minerva Ginecol*. 2015;67(4):301-6.
5. Kalem Z, Kaya AE, Bakirarar B, Basbug A, Kalem MN. An Optimal Uterine Closure Technique for Better Scar Healing and Avoiding Isthmocele in Cesarean Section: A Randomized Controlled Study. *J Invest Surg*. 2021;34(2):148-56.
6. Calzolari S, Sisti G, Pavone D, Ciocia E, Bianchini N, Cozzolino M. Prevalence of Infertility Among Patients With Isthmocele and Fertility Outcome After Isthmocele Surgical Treatment: A Retrospective Study. *Ochsner J*. 2019;19(3):204-9.
7. Kulshrestha V, Agarwal N, Kachhawa G. Post-caesarean Niche (Isthmocele) in Uterine Scar: An Update. *J Obstet Gynaecol India*. 2020;70(6):440-6.
8. Asoglu MR, Celik C, Ozturk E, Cavkaytar S, Bahceci M. Impact of Isthmocele on Assisted Reproductive Treatment Outcomes: An Age-matched Retrospective Study. *J Minim Invasive Gynecol*. 2021;28(5):1113-20.
9. Morris H. Surgical pathology of the lower uterine segment caesarean section scar: is the scar a source of clinical symptoms? *International journal of gynecological pathology : official journal of the International Society of Gynecological Pathologists*. 1995;14(1):16-20.
10. Bij de Vaate AJ, Brölmann HA, van der Voet LF, van der Slikke JW, Veersema S, Huirne JA. Ultrasound evaluation of the Cesarean scar: relation between a niche and postmenstrual spotting. *Ultrasound Obstet Gynecol*. 2011;37(1):93-9.
11. Gupta T, Singal K, Gupta N, Kohli S, Kanyal M. Comparative Study of USG and MRI in Evaluation of Isthmocele. *J Obstet Gynaecol India*. 2021;71(3):292-6.
12. Borges LM, Scapinelli A, de Baptista Depes D, Lippi UG, Coelho Lopes RG. Findings in patients with postmenstrual spotting with prior cesarean section. *J Minim Invasive Gynecol*. 2010;17(3):361-4.
13. Karampelas S, Salem Wehbe G, de Landsheere L, Badr DA, Tebache L, Nisolle M. Laparoscopic Isthmocele Repair: Efficacy and Benefits before and after Subsequent Cesarean Section. *J Clin Med*. 2021;10(24).
14. Mashiach R, Burke YZ. Optimal Isthmocele Management: Hysteroscopic, Laparoscopic, or Combination. *J Minim Invasive Gynecol*. 2021;28(3):565-74.
15. Vitale SG, Ludwin A, Vilos GA, Torok P, Tesarik J, Vitagliano A, *et al.* From hysteroscopy to laparoscopic surgery: what is the best surgical approach for symptomatic isthmocele? A systematic review and meta-analysis. *Arch Gynecol Obstet*. 2020;301(1):33-52.
16. Candiani M, Ferrari SM, Marotta E, Tandoi I, Ottolina J, Salvatore S. Mini-invasive transvaginal repair of isthmocele: a video case report. *Fertil Steril*. 2019;111(4):828-30.
17. Zeller A, Villette C, Fernandez H, Capmas P. Is Hysteroscopy a Good Option to Manage Severe Cesarean Scar Defect? *J Minim Invasive Gynecol*. 2021;28(7):1397-402.
18. Szafarowska M, Biela M, Wichowska J, Sobocinski K, Segiet-Swiecicka A, Doniec J, *et al.* Symptoms and Quality of Life Changes after Hysteroscopic Treatment in Patients with Symptomatic Isthmocele-Preliminary Results. *J Clin Med*. 2021;10(13).

19. Shapira M, Mashiach R, Meller N, Watad H, Baron A, Bouaziz J, *et al.* Clinical Success Rate of Extensive Hysteroscopic Cesarean Scar Defect Excision and Correlation to Histologic Findings. *J Minim Invasive Gynecol.* 2020;27(1):129-34.
20. Vegas Carrillo de Albornoz A, Lopez Carrasco I, Montero Pastor N, Martin Blanco C, Miro Matos M, Alonso Pacheco L, *et al.* Outcomes after Hysteroscopic Treatment of Symptomatic Isthmoceles in Patients with Abnormal Uterine Bleeding and Pelvic Pain: A Prospective Case Series. *Int J Fertil Steril.* 2019;13(2):108-12.
21. Setubal A, Alves J, Osorio F, Sidiropoulou Z. Demonstration of Isthmocele Surgical Repair. *J Minim Invasive Gynecol.* 2021;28(3):389-90.
22. Tsuji S, Kimura F, Yamanaka A, Hanada T, Hirata K, Takebayashi A, *et al.* Impact of hysteroscopic surgery for isthmocele associated with cesarean scar syndrome. *J Obstet Gynaecol Res.* 2018;44(1):43-8.
23. Muzii L, Domenici L, Lecce F, Di Felicianantonio M, Frantellizzi R, Marchetti C, *et al.* Clinical outcomes after resectoscopic treatment of cesarean-induced isthmocele: a prospective case-control study. *Eur Rev Med Pharmacol Sci.* 2017;21(15):3341-6.
24. Raimondo G, Grifone G, Raimondo D, Seracchioli R, Scambia G, Masciullo V. Hysteroscopic treatment of symptomatic cesarean-induced isthmocele: a prospective study. *J Minim Invasive Gynecol.* 2015;22(2):297-301.